

Black Seed Oil Protects Against Levofloxacin Hepatotoxicity: Analyses of the Biochemical and Histopathological Effects

by Yulia Yusrini Djabir

Submission date: 22-Nov-2022 01:12PM (UTC+0700)

Submission ID: 1961050771

File name: yuliyusrini-A-10-854-2-2dcd812.pdf (1.06M)

Word count: 4994

Character count: 27622

Research Paper

Black Seed Oil Protects Against Levofloxacin Hepatotoxicity: Analyses of the Biochemical and Histopathological Effects



Nurfadilah Nurfadilah¹, Yulia Yusrini Djabir^{2*}, Siti Aminah³, Yulita Chrismensi Patimang⁴, Arif Santoso⁴, Risfah Yulianty⁴

1. Faculty of Pharmacy, Hasanuddin University, Makassar, Indonesia.
2. Laboratory of Clinical Pharmacy, Faculty of Pharmacy, Hasanuddin University, Makassar, Indonesia.
3. Department of Pulmonology, Faculty of Medicine, Hasanuddin University, Indonesia, Makassar.
4. Laboratory of Pharmaceutical Chemistry, Faculty of Pharmacy, Hasanuddin University, Makassar, Indonesia.



How to cite this paper Nurfadilah N, Yusrini Djabir Y, Aminah S, Chrismensi Patimang Y, Santoso A, Yulianty R. Black Seed Oil Protects Against Levofloxacin Hepatotoxicity: Analyses of the Biochemical and Histopathological Effects. *Iranian Journal of Toxicology*. 2022; 16(4):237-246. <http://dx.doi.org/10.32598/IJT.16.4.854.2>



Article info:

Received: 09 May 2022

Accepted: 23 Jul 2022

Online Published: 01 Oct 2022

*** Corresponding author:**
Yulia Yusrini Djabir, PhD.

Address: Laboratory of Clinical Pharmacy, Faculty of Pharmacy, Hasanuddin University, Makassar, Indonesia.
E-mail: yulia.yusrini@unhas.ac.id

ABSTRACT

Background: Long-term use of levofloxacin can cause alterations in the liver function. This study aimed to determine the protective effect of black seed oil (BSO) against liver injury due to levofloxacin administration in rats.

Methods: The chemical composition of BSO was analyzed with gas chromatography and mass spectrophotometry (GC-MS). Rats (n=30) were treated daily with levofloxacin and BSO at three doses (1, 2 or 4 mL/kg) orally for 28 days. The presence of liver injury was determined based on serum biomarkers and liver malondialdehyde (MDA) levels, and histopathological examinations.

Results: The GC-MS analyses showed that BSO contained 25 chemical compounds, including thymoquinone (10.14%). The levofloxacin administration significantly increased the liver enzymes and MDA levels, and induced a marked alteration in the liver histological structures. Treatment of rats with one or two mL/kg BSO significantly decreased the liver enzymes, and MDA levels compared to those that received levofloxacin alone (P<0.05). However, the highest dose (4 mL/kg) BSO failed to improve liver MDA levels. The recovery of liver histological damages was also observed in rats treated with BSO.

Conclusion: It was concluded that the BSO administration reduced the liver dysfunction due to levofloxacin at doses of 1 or 2 mL/kg, but not at 4 mL/kg. Further research is warranted to explore if the protective effect of BSO is associated with its antioxidant properties.

Keywords: Black seed oil, Histopathology, Levofloxacin, Liver injury, *Nigella Sativa*

Introduction

The eradication of tuberculosis is challenged by a rise in the number of multidrug-resistant tuberculosis (MDR-TB) cases worldwide [1]. Levofloxacin, an antibiotic from the fluoroquinolone group, is one of the most common drugs

used for MDR-TB cases [2]. This drug inhibits DNA supercoiling in *Mycobacterium tuberculosis*, thus damaging the DNA replication by interfering with its gyrase activity [3]. However, levofloxacin may induce hepatotoxicity characterized by elevated liver enzymes, i.e. alanine and aspartate aminotransferases (ALT & AST) levels [4]. The hepatotoxicity secondary to levofloxacin administration may occur after 5-14 days of the

therapy initiation [5, 6]. Cases of hepatotoxicity have been reported in a number of patients who received levofloxacin for the management of their MDR-TB [7]. In this context, retrospective data from 746 patients have demonstrated an increase in the incidence of hepatotoxicity during treatment with fluoroquinolone drugs, especially levofloxacin and moxifloxacin [8].

The hepatotoxicity management remains limited due to lack of approved drugs with adequate hepatoprotective properties. Studies have reported the beneficial effects of black seed oil (BSO) extracted from the plant, *Nigella sativa*, on the prevention of drug-induced liver injury [9]. This oil has been shown to contain several bioactive compounds, including thymoquinone, thymohydroquinone, dithymoquinone, p-cymene, carvacrol, 4-terpineol, and t-anethol [10]. Thymoquinone has been demonstrated to inhibit oxidative stress by increasing the activity of the antioxidant enzymes, such as superoxide dismutase and glutathione peroxidase, and reducing the lipid peroxidase activity [11]. Since the toxicity by levofloxacin occurs mainly due to diminished glutathione supplies [12], strengthening the body's defense system with antioxidants would be essential to overcome the oxidative stress-related cellular damages. This study was planned to investigate the antioxidant effect of black seed oil on the liver function in rats after levofloxacin administration at subacute doses.

Materials and Methods

Chemicals and drugs: The black seed oil (BSO) was obtained from black cumin seed (*Nigella sativa*) purchased from Al-waqia'ah supplier (Makassar, Indonesia). Levofloxacin tablets (Hexpharm Jaya[®]) were obtained from a licensed pharmaceutical store in Makassar, Indonesia. Thiobarbituric acid (TBA, Sigma-Aldrich), 1,1,3,3-tetra methoxy propane (TMP, Sigma-Aldrich), and Trichloroacetic Acid (TCA, Merck) were ordered via the official suppliers in Indonesia. The diagnostic kits for AST, ALT, and GGT were obtained from Human Diagnostics Worldwide (Wiesbaden, Germany).

Chemical constituents analyses: Prior to the in vivo experiments, a laboratory analysis was conducted to identify the chemical constituents of the BSO samples used in this study. The analysis was performed using a Trace 1310 gas chromatography with TSQ 8000 Evo mass spectrometry (Thermo Scientific; Mundelein, IL, USA). The column size was 20 mm x 0.18 mm (TG-5MS) with helium gas used as the carrier. The oven had an initial and final temperature of 50°C and 330°C, respectively, at an increasing rate of 10 to 25°C/minutes.

Preparation of animals: The experimental animals used in this study were 30 male albino rats (*Rattus norvegicus*) at an average weight of 200-300 g each. They were acclimatized to the laboratory environment for 14 days prior to the treatments. The rats had free access to standard food pellets and drinking water throughout the study. The animal care protocol used was based on the institution's animal care standards, which had already been granted an ethical clearance (318/UN4.6.4.5.31/PP36/2020).

Preparation of Levofloxacin and Black Seed Oil: The levofloxacin dosage used in this study was based on that for humans (15 mg/kg/body weight/day), which was converted to animal dosage as described by Nair and Jacob's guideline [13]. Accordingly, the levofloxacin dose was 93 mg/kg per rat. At this dose, levofloxacin has previously been shown to sufficiently induce renal toxicity in rats [14]. The levofloxacin powder was prepared as suspension, using 1% sodium carboxymethyl cellulose (Na-CMC) immediately before administration. The BSO was diluted in corn oil at three different concentrations, i.e. 10%, 20%, and 40%, and the volume of administration was one mL/200g per rat's body weight. These concentrations were equivalent to the BSO doses of one, two or four mL/kg, respectively.

Experimental protocol: The animals were divided into five groups of six each as follows: 1) healthy controls, 2) levofloxacin group (rats received levofloxacin suspension and corn oil as a placebo), and, 3, 4, 5) treatment groups that received BSO at either of three doses of one, two or four mL/kg body weight. The BSO treatment was given two hours before the daily levofloxacin administration for 28 days. The blood samples were collected one day before starting the study (day 0) and a day after the last treatment (day 29). Following the final blood sampling, a necropsy was performed to harvest the rats' livers for further analyses. The right lobe of the liver was fixed in 10% formaldehyde diluted in phosphate buffered saline (PBS) for histopathological examination. The left lobe was immersed in liquid nitrogen and stored in a freezer at minus 20°C for malondialdehyde (MDA) analysis.

Serum biomarkers analyses: The collected blood samples were centrifuged at 3000 rpm for 20 minutes. Next, we analyzed the serum levels of alanine aminotransferase (ALT), aspartate aminotransferase (AST), and gamma-glutamyl transferase (GGT) according to the kits' instructions provided by the supplier. A 100 µl aliquot of each blood plasma was mixed with 1000 µl PBS, homogenized, and incubated for five minutes at

37°C. After the incubation, 250 µl of the substrate kit was added, homogenized, and re-incubated for one minute at 37°C. All of the serum biomarker levels were measured at 340 nm, using Humalyzer 3500 (Hamburg, Germany).

6. Liver Malondialdehyde Analyses: The MDA analysis was carried out according to the method described by a previous study [15]. A rat liver sample weighing 400mg, was ground in a mortar and pestle, and homogenized in PBS at pH 7.4. The homogenate was centrifuged at 3000 rpm for 10 minutes. A 0.5 mL supernatant from each homogenate was mixed with 1 mL 1% TBA and 1 mL of 10% TCA before being placed in a water bath at 90°C for 20 minutes. The absorbance was then measured at 531 nm, using a UV-visible spectrophotometer.

Histopathological examinations: After 48-hour storage in formaldehyde, the liver specimens were cut into 0.5-1cm thickness, stored in embedding cassettes, and homogenized in a tissue processor (Thermo Scientific; Bedford, MA, USA). The specimens were embedded in paraffin blocks and sliced into 4-5 µm thickness, using a microtome, then floated on a warm water bath at 40°C. The specimens were placed on glass slides and dried, using an electric hotplate for at least 2 hours before being stained with hematoxylin and eosin (H&E) and then covered with glass slides. The histopathological examination was conducted under a light microscope

(Olympus; Tokyo, Japan) equipped with a Nikon camera. The photomicrographs were taken at 100X and 400X magnifications. The liver histological damages were examined independently by two expert murine pathologists who were blinded to the animal grouping.

The antioxidative activity of BSO samples was tested against radicals, using 2,2-diphenyl-1-picrylhydrazyl-hydrate (DPPH). The half maximal inhibitory concentration (IC₅₀) values were determined by measuring the absorbance of a series of BSO concentrations, using a UV-visible spectrophotometer at 515nm. The IC₅₀ values were then plotted in the form of a concentration-response curve.

Statistical analyses: The normal distribution of data was determined using Shapiro-Wilk's and one-way ANOVA analyses, and finally by Tukey's HSD test to determine significant differences among the groups. The data were presented as the mean±standard deviations. The level of statistical significance was set at P<0.05.

Results

1. Chemical Constituents: The gas chromatography and mass spectrophotometry (GC-MS) analyses of BSO revealed 25 peaks on the chromatogram, suggestive of 25 volatile chemical compounds being present

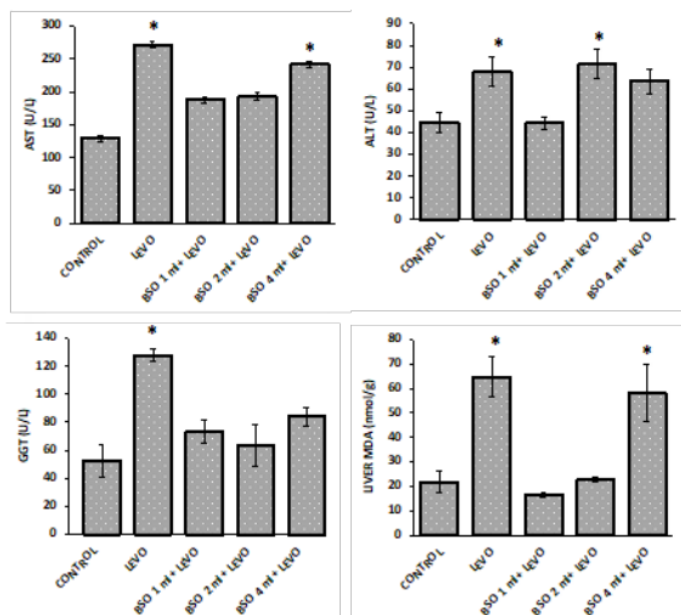


Figure 1. Comparison of liver biomarker levels among the rat groups after treatments

*P<0.05 compared to the control group.

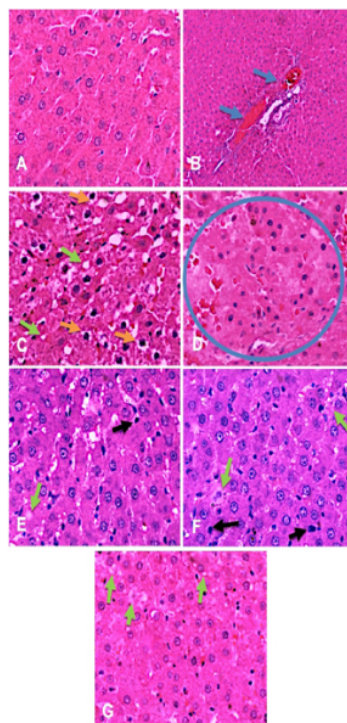


Figure 2. Comparison of rats' liver microphotographs after 28 days of exposure to different treatments

A: Control; B-D: Levofloxacin; E: Black seed oil 1 mL/kg; F: Black seed oil 2 mL/kg; G: Black seed oil 4 mL/kg. Congestion (blue arrow), fatty degeneration and vacuolization (green arrow), hydropic and ballooning degeneration (yellow arrow), necrotic cells (black arrow), and areas of necrosis (blue circle). H&E staining at 100x and 400x magnification.

ent in BSO (Table 1). These tests revealed six major constituents as follows: a) 9,12-octadecadienoic acid (Z, Z) (44.94%); b) bicyclo (3.1.0) hex-2-ene, 4-methyl-1-(1-methylethyl) (10.23%); c) thymoquinone (10.14%); d) o-Cymer (9.05%); e) n-hexadecanoic acid (8.25%); and f) 9,12-Octadecadienoic acid (Z, Z)-2,3-dihydroxypropyl ester (6.95%).

Liver Biomarkers: The liver enzymes, such as AST, ALT, and GGT, were significantly elevated after the rats received levofloxacin (93 mg/kg) for 28 days ($P < 0.05$; Figure 1). The elevations of the liver enzymes suggest the occurrence of damages to the hepatocytes. Simultaneously, the MDA levels in the liver tissue samples also increased by approximately 3-fold compared to those of the controls ($P < 0.05$). Compared to levofloxacin group, pre-treatment with black seed oil at 1 mL/kg induced a substantial decrease in the liver biomarkers' levels ($P < 0.05$; Figure 1). The reductions in the MDA levels were not dose-dependent. Compared to the 1 mL/kg dose, the administration of BSO at 2 mL/kg reduced

the AST, GGT, and MDA levels but did not change the ALT levels. Interestingly, the liver biomarkers were not reduced, in the groups treated with BSO at 4 mL/kg.

Histopathological Analyses: Figure 2 represents the results of the histopathological observations under light microscopy after H&E staining. In the normal controls, the rat liver samples showed normal cellular architecture with no or minimal damages. In contrast, the liver tissue samples from the rats treated with levofloxacin but without BSO were characterized by large areas of hydropic degeneration, ballooning hepatocytes, lipid degeneration, vacuolization, congestion and signs of hemorrhage (Figures 2B & 2C). The histological damages were diffuse and mostly evident in over 50% of the observed areas at 400x magnification (Figure 2D).

In general, the group that was pre-treated with BSO at 1 mL/kg showed minimal damages, with the cells demonstrating lipid degeneration and necrosis (Figure 2E). These histopathological changes only affected a

Table 1. Chemical compounds found in the black seed oil based on GC-MS analysis

No	RT.	Molecular Formula	Compound Title**	% Area
1	4.00	C ₁₀ H ₁₆	²⁰ bicyclo[3.1.0]hex-2-ene, 4-methyl-1-(1-methyl ethyl)-	10.23
2	4.89	C ₁₀ H ₁₄	o-Cymene	9.05
3	5.58	C ₁₁ H ₂₀ O	cis-4-methoxy thujane	3.19
4	6.00	²⁵ C ₁₀ H ₁₈ O	3-Cyclohexen-1-ol,4-methyl-1-(1-methylethyl)-, (R)-	0.80
5	6.16	C ₁₀ H ₁₆ O	³⁷ 1-Cyclohexene-1-carboxaldehyde, 2,6,6-trimethyl-	0.53
6	6.50	C ₁₀ H ₁₂ O ₂	Thymoquinone	10.14
7	7.29	³¹ C ₁₅ H ₂₄	Tricyclo [5.4.0.0 (2,8)] undec-9-ene	0.55
8	7.74	C ₁₅ H ₂₄	Longifolene	1.81
9	8.60	C ₁₅ H ₂₄ O	⁴⁸ Phenol, 4-methoxy-2,3,6-trimethyl-	1.24
10	8.86	C ₁₄ H ₂₆ O	7-Tetradecenal, (Z)-	0.08
11	9.68	C ₁₅ H ₂₆ O	Humulene-1,6-dien-3-ol	0.09
12	9.92	C ₁₂ H ₂₀ O	4,8-Decadienal,5,9-dimethyl-	0.69
13	10.17	C ₁₆ H ₃₂ O ₂	Butyric acid, dodecyl ester	0.07
14	11.42	²⁶ C ₁₆ H ₃₂ O ₂	n-Hexadecanoic acid	8.25
15	12.76	C ₁₈ H ₃₂ O ₂	³⁸ 9,12-Octadecadienoic acid (Z,Z)-	44.94
16	16.36	C ₂₇ H ₅₀ O ₄ Si ₂	9-Octadecatrienoic acid, 2-[trimethylsilyloxy]-1-[(trimethylsilyl)oxymethyl] ethyl ester	0.32
17	16.67	C ₁₂ H ₂₀ O ₄	⁷ 9,12-Octadecadienoic acid (Z,Z)-2,3-dihydroxy propyl ester	6.95
18	17.58	C ₃₇ H ₇₆ O	1-Heptatriacotanol	0.22
19	18.00	C ₂₇ H ₅₄ O ₄ Si ₂	1-Monolinoleoylglycerol trimethylsilyl ether	0.20
20	18.47	C ₂₀ H ₂₆ N ₂ O ₂	Dasycarpidan-1-methanol-acetate (ester)	0.13
21	18.91	C ₂₇ H ₅₂ O ₄ Si ₂	9,12,15-Octadecatrienoic acid	0.06
22	19.12	C ₂₇ H ₅₄ O ₄ Si ₂	1-Monolinoleoylglycerol trimethylsilyl ether	0.10
23	19.68	C ₂₇ H ₅₄ O ₄ Si ₂	1-Monolinoleoylglycerol trimethylsilyl ether	0.07
24	20.62	C ₂₇ H ₅₄ O ₄ Si ₂	1-Monolinoleoylglycerol trimethylsilyl ether	0.06
25	22.10	C ₂₇ H ₅₄ O ₄ Si ₂	1-Monolinoleoylglycerol trimethylsilyl ether	0.23
Total				100

small number of cells as observed under light microscopy at 400x magnification (Figure 2E). Similarly, most rats treated with BSO at 2 mL/kg also showed normal liver tissue features apart from a low number of cells with lipid degeneration and necrosis (Figure 2F). Meanwhile, the group treated with BSO at 4 mL/kg appeared to have minimal to mild liver damages (Figure 2G). The

histopathological changes observed were mostly characterized as lipid degeneration, swollen cytoplasm, and vacuolization of hepatocytes due to lipid accumulations.

³⁹ **DPPH Scavenging Activity:** The DPPH assay estimated the antioxidant activity of BSO by the mechanism associated with free radical scavenging. It was found

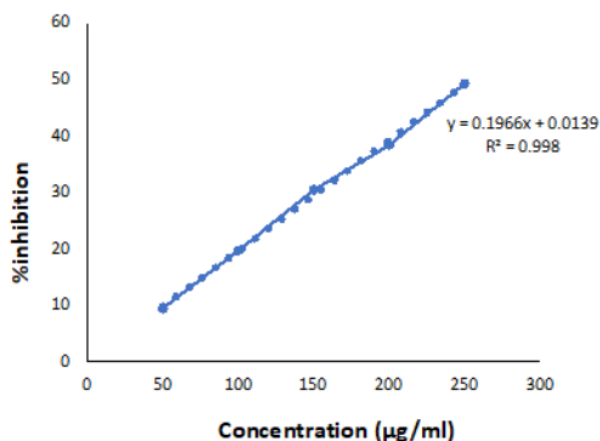


Figure 3. Dose-response plot of black seed oil free radical scavenging activity, using DPPH test

Based on the equation shown above, the IC_{50} of clove oil was less than 250 µg/mL.

that the IC_{50} of the BSO samples used was greater than 250 µg/mL based on the concentration-response curve as shown in Figure 3.

Discussion

Since the hepatotoxic side effects of levofloxacin might be serious or even life-threatening, it is imperative to explore therapeutic strategies aimed at preventing or minimizing the induced toxicity. Several studies have reported the beneficial effects of black seed oil (BSO) and some parts of *Nigella arvensis* plant, suggestive of significant antioxidant and anti-inflammatory properties [16]. These therapeutic effects are likely to be very useful in protecting against levofloxacin-induced toxicity in the liver.

It has been reported that BSO may contain 22-38% fixed oil, including linoleic acid, oleic acid, tocopherols, retinol, carotenoids, thymoquinone, and about 0.40-1.50% volatile oil [17]. Among the essential oils, the main constituent is mostly thymoquinone (14-28%), a potent antioxidant and anti-inflammatory agent [17-19]. However, based on GC-MS analyses, the BSO sample used in this study had a lower thymoquinone content (10.14%) compared to those reported by earlier studies [17-19]. The thymoquinone content of BSO may vary based on the origin of the plants and the extraction method used. This may emphasize the need for standardizing the BSO products that are commercially available as food supplements.

In this study, BSO's protective effect on the liver was evaluated versus the levofloxacin's toxicity. Fluoroquinolone antibiotics, including levofloxacin, can have serious side effects since they cause permanent damage to the liver that may be fatal [20]. The incidences of levofloxacin induced-hepatotoxicity have been reported by many studies, which is characterized by increased levels of liver enzymes, such as AST, ALT, ALP, and bilirubin, diffuse hepatocellular necrosis, and intense cellular degeneration [4-6]. The results of this study demonstrated that daily administration of levofloxacin for 28 days caused marked elevations of AST, ALT, GGT and MDA levels. However, treatment with BSO at 1 mL/kg before levofloxacin administration halted the elevation of all liver injury biomarker levels, including the MDA.

MDA is a product of lipid peroxidation, hence, the surge in the liver MDA level is suggestive of increased lipid peroxidation in the rats' liver after levofloxacin administration. The hepatotoxic effect of drugs is often associated with oxidative stress, resulting from an imbalance between the antioxidant cellular system and the generation of reactive oxygen species [21]. Nevertheless, the BSO treatment only reduced the liver MDA levels at 1 or 2 mL/kg, but not at 4 mL/kg. This finding suggests that the hepatoprotective effect of BSO was dose-dependent.

To confirm the antioxidative effect of BSO, a DPPH assay was conducted. This compound is highly stable and reacts with antioxidants by accepting hydrogen atoms [22]. The IC_{50} value of the BSO in this study was higher than 250 µg/mL. Another study has shown

that the capability of BSO to trap radical DPPH may vary depending on its variety. For instance, BSO from Australia has an IC_{50} value of about 460 $\mu\text{g/mL}$, while the Turkish variety presents an IC_{50} of 515 $\mu\text{g/mL}$ [18]. It is important to note that the antiradical activities of BSO can be influenced by a range of factors, including the plant's growth environment, seed and oil storage, and the extraction process. In this study, we did not directly compare the IC_{50} value of the BSO samples with other standard antioxidants. Obviously, it may be necessary to provide a quantitative basis for the BSO radical scavenging activity [23]. Further studies are warranted to clarify this matter.

The levofloxacin administration not only increased the liver enzyme levels, but also induced marked degenerations in the hepatocytes. Unlike other drug-induced hepatotoxicities where the inflammatory reaction is often evident in the liver tissues [24, 25], there was no inflammatory cell infiltration in the rats treated with levofloxacin. Instead, lipid and hydropic degenerations were the hallmarks of the histopathological changes observed in our study. A similar result has also been observed in mice treated with levofloxacin, where swollen hepatocytes, necrosis, vacuolization, and pyknosis have been the most evident changes in the liver [26].

With BSO treatment, the presence of histological damages in the levofloxacin-treated rats were markedly reduced at all given doses, especially at one or two mL/kg groups. This is consistent with the results of other studies that tested the hepatoprotective effects of BSO against paracetamol [27], carbon tetrachloride [28], and vitaminosis-induced toxicities [29]. The protective effects of *Nigella sativa* have been not only demonstrated in the liver, but also in other organs, including heart [30], gastrointestinal tract [31], and the kidneys [14]. Its antioxidant compound, i.e. thymoquinone, has been shown in an earlier study [32] to prevent a decline in the activity of liver antioxidants, such as superoxide dismutase, catalase, and glutathione peroxidase, and non-enzymatic antioxidants, such as Vitamins A, E, and C. Given the findings of this and other studies, the protective effect of black seed oil is likely to stem from its radical scavenging activity and inhibiting the lipid peroxidation in the liver, which protect the integrity of the liver hepatocytes.

Conclusions

27

Black seed oil from the *Nigella sativa* plant has protective effects against liver toxicity induced following 28 days of levofloxacin administration. The hepatoprotective effect was confirmed by significant declines in the liver enzymes found in the serum, improved liver tissue injury, and reduced liver malondialdehyde level. The most protection was found when the black seed oil was administered at doses of 1 or 2 mL/kg per rat. This protective effect is likely to find useful applications in clinical settings in humans.

12

Ethical Considerations

Compliance with ethical guidelines

The animal care protocol was carried out based on the institution's animal care guidelines. The study protocol was reviewed and approved prior to conducting the experiments (Institutional Registration #: 318/UN4.6.4.5.31/PP36/2020).

Funding

Funding for this study was provided by the Ministry of Research, Technology and Higher Education, the Republic of Indonesia.

10

Authors' contributions

All authors equally contributed to preparing this article.

Conflict of interest

The authors declare no conflict of interests with any internal or external entities in conducting this study.

Acknowledgements

19

This study received a research grant from the Ministry of Research, Technology and Higher Education of Republic of Indonesia. The authors appreciate the professors, management and staff of Laboratory of Clinical Pharmacy, Faculty of Pharmacy, Hasanuddin University, Indonesia, for their assistance with this research project.

References

- [1] World health organization (WHO). Global tuberculosis report 2020. Geneva: World Health Organization; 2020. [Link]
- [1] Mase SR, Chorba T. Treatment of drug-resistant tuberculosis. *Clinics in Chest Medicine*. 2019; 40(4):775-95. [DOI:10.1016/j.ccm.2019.08.002] [PMID] [PMCID]
- [2] Wentzell L, Maxwell A. The complex of DNA gyrase and quinolone drugs on DNA forms a barrier to the ϵ DNA polymerase replication complex. *Journal of Molecular Biology*. 2001; 304:779-91. [DOI:10.1006/jmbi.2000.4266] [PMID]
- [3] Adikwu E. Fluoroquinolones reported hepatotoxicity. *Pharmacology & Pharmacy*. 2012; 3(3):328-36. [DOI:10.4236/pp.2012.33044]
- [4] Schloss M, Becak D, Tosto ST, Velayati A. A case of levofloxacin-induced hepatotoxicity. *American Journal of Case Reports*. 2018; 19:272-6. [DOI:10.12659/AJCR.907440] [PMID] [PMCID]
- [5] Figueira-Coelho J, Pereira O, Picado B, Mendonça P, Neves-Costa J, Neta J. Acute hepatitis associated with the use of levofloxacin. *Clinical Therapeutics*. 2010; 32(10):1733-7. [DOI:10.1016/j.clinthera.2010.09.004] [PMID]
- [6] Richeldi L, Covi M, Ferrara G, Franco F, Vailati P, Meschiari E, et al. Clinical use of levofloxacin in the long term treatment of drug resistant tuberculosis. *Monaldi Archives for Chest Disease*. 2002; 57:39-43. [PMID]
- [7] Paterson JM, Mamdani MM, Manno M, Juurlink DN. Fluoroquinolone therapy and idiosyncratic acute liver injury: A population-based study. *CMAJ - Canadian Medical Association Journal*. 2012; 184(14):1565-70. [DOI:10.1503/cmaj.111823] [PMID] [PMCID]
- [8] Mollazadeh H, Hosseinzadeh H. The protective effect of nigella sativa against liver injury: A review. *Iranian Journal of Basic Medical Sciences*. 2014; 17(12):958-66. [PMID] [PMCID]
- [9] Harzallah H, Kouidhi B, Flamini G, Bakhrouf A, Mahjoub T. Chemical composition, antimicrobial potential against cariogenic bacteria and cytotoxic activity of tunisian nigella sativa essential oil and thymoquinone. *Food Chemistry*. 2011; 129:1469-74. [DOI:10.1016/j.foodchem.2011.05.117]
- [10] Mansour MA, Nagi MN, El-Khatib AS, Al-Bekairi AM. Effects of thymoquinone on antioxidant enzyme activities, lipid peroxidation and dt-diaphorase in different tissues of mice: A possible mechanism of action. *Cell Biochemistry and Function*. 2002; 20(2):143-51. [DOI:10.1002/cbf.968] [PMID]
- [11] Talla V, Veerareddy P. Oxidative stress induced by fluoroquinolones on treatment for complicated urinary tract infections in indian patients. *Journal of Young Pharmacists*. 2011; 3(4):304-9. [DOI:10.4103/0975-1483.90242] [PMID] [PMCID]
- [12] Nair AB, Jacob S. A simple practice guide for dose conversion between animals and human. *Journal of Basic and Clinical Pharmacy*. 2016; 7:27-31. [DOI:10.4103/0976-0105.177703] [PMID] [PMCID]
- [13] Fiqardina A, Djabir YY, Santoso A, Salsabil NS, Ismail I. The nephroprotective effect of clove oil (oleum caryophylli) against levofloxacin toxicity in rats. *Iranian Journal of Toxicology*. 2022; 16(1):27-34. [DOI:10.32598/IJT.16.1.854.1]
- [14] Djabir Y, Adnan J, Amaliah N, RamLi N, Sartini S, Mameda S, et al. Roselle (hibiscus sabdariffa l.) calyx water extract ameliorates isoniazid and rifampicin induced liver and renal injuries in rats. *Journal of Herbmec Pharmacology*. 2021; 10(3):296-303. [DOI:10.34172/jhp.2021.34]
- [15] Bourgou S, Pichette A, Marzouk B, Legault J. Antioxidant, anti-inflammatory, anticancer and antibacterial activities of extracts from nigella sativa (black cumin) plant parts. *Journal of Food Biochemistry*. 2012; 36(5):539-46. [DOI:10.1111/j.1745-4514.2011.00567.x]
- [16] Amin B, Hosseinzadeh H. Black cumin (nigella sativa) and its active constituent, thymoquinone: An overview on the analgesic and anti-inflammatory effects. *Planta Medica*. 2016; 82(1/2):8-16. [DOI:10.1055/s-0035-1557838] [PMID]
- [17] Burits M, Bucar F. Antioxidant activity of Nigella sativa essential oil. *Phytotherapy Research*. 2000; 14(5):323-8. [DOI:10.1002/1099-1573(200008)14:5<323::AID-PTR621>3.0.CO;2-Q]
- [18] Singh S, Das SS, Singh G, Schuff C, de Lampasona MP, Catalán CAN. Composition, in vitro antioxidant and antimicrobial activities of essential oil and oleoresins obtained from black cumin seeds (nigella sativa l.). *BioMed Research International*. 2014; 2014:918209. [DOI:10.1155/2014/918209] [PMID] [PMCID]
- [19] Baggio D, Ananda-Rajah MR. Fluoroquinolone antibiotics and adverse events. *Australian Prescriber*. 2021; 44(5):161-4. [DOI:10.18773/austprescr.2021.035] [PMID] [PMCID]
- [20] Pizzino G, Irrera N, Cucinotta M, Pallio G, Mannino F, Arcoraci V, et al. Oxidative stress: Harms and benefits for human health. *Oxidative Medicine and Cellular Longevity*. 2017; 2017:8416763. [DOI:10.1155/2017/8416763] [PMID] [PMCID]
- [21] Kedare SB, Singh RP. Genesis and development of dpph method of antioxidant assay. *Journal of Food Science and Technology*. 2011; 48(4):412-2. [DOI:10.1007/s13197-011-0251-1] [PMID] [PMCID]
- [22] Molyneux P. The use of the stable free radical diphenylpicrylhydrazyl (dpph) for estimating antioxidant activity. *Songklanakarin Journal of Science and Technology*. 2004; 26(2):211-9. [Link]
- [23] Djabir YY, Arsyad A, Usmar U, Wahyudin E, Arwi H, Rupang IS. The stages of development of liver and renal injuries in rats induced by fixed dose combination of antituberculosis regimen. *FABAD Journal of Pharmaceutical Sciences*. 2020; 45(1):29-35. [Link]
- [24] Djabir YY, Arsyad A, Murdifin M, Tayeb R, Amir MN, Kamaruddin FA, et al. Kleinhovia hospita extract alleviates experimental hepatic and renal toxicities induced by a combination of antituberculosis. *Journal of Herbmec Pharmacology*. 2021; 10(1):102-8. [DOI:10.34172/jhp.2021.10]
- [25] Ara C, Asmatullah A, Kanwal S, Chaudhary A, Siddiqua A. Hematological and histopathological analyses of levofloxacin induced toxicity in mammals. *Punjab University Journal of Zoology*. 2020; 35(1):1-6. [DOI:10.17582/journal.pujz/2020.35.1.01.06]
- [26] Adam GO, Rahman MM, Lee S-J, Kim G-B, Kang H-S, Kim J-S, et al. Hepatoprotective effects of nigella sativa seed extract against acetaminophen-induced oxidative stress. *Asian Pacific Journal of Tropical Medicine*. 2016; 9(3):221-7. [DOI:10.1016/j.apjtm.2016.01.039] [PMID]



- [27] Danladi J, Abdulsalam A, Timbuk J, Ahmed S, Mairiga A, Dahiru A. Hepatoprotective effect of black seed (nigella sativa) oil on carbon tetrachloride (ccl4) induced liver toxicity in adult wistar rats. *Journal of Dental and Medical Sciences (IOSR-JDMS)*. 2013; 4(3):56-62. [DOI:10.9790/0853-0435662]
- [28] Al-Suhaimi EA. Hepatoprotective and immunological functions of Nigella sativa seed oil against hypervitaminosis a in adult male rats. *International Journal for Vitamin and Nutrition Research*. 2012; 82(4):288-97. [DOI:10.1024/0300-9831/a000121] [PMID]
- [29] Ahmed MA, Hassanein KM. Cardio protective effects of nigella sativa oil on lead induced cardio toxicity: Anti inflammatory and antioxidant mechanism. *Journal of Physiology and Pathophysiology*. 2013; 4(5):72-80. [DOI:10.5897/JPAP2013.0083]
- [30] Rifat-Uz-Zaman MS, Khan MS. Gastroprotective and anti-secretory effect of Nigella sativa seed and its extracts in indomethacin-treated rats. *Pakistan Journal of Biological Sciences*. 2004; 7:995-1000. [DOI:10.3923/pjbs.2004.995.1000]
- [31] Hannan MA, Rahman MA, Sohag AAM, Uddin MJ, Dash R, Sikder MH, et al. Black cumin (nigella sativa L): A comprehensive review on phytochemistry, health benefits, molecular pharmacology, and safety. *Nutrients*. 2021; 13(6):1784. [DOI:10.3390/nu13061784] [PMID] [PMCID]

This Page Intentionally Left Blank

Black Seed Oil Protects Against Levofloxacin Hepatotoxicity: Analyses of the Biochemical and Histopathological Effects

ORIGINALITY REPORT

19%

SIMILARITY INDEX

16%

INTERNET SOURCES

14%

PUBLICATIONS

5%

STUDENT PAPERS

PRIMARY SOURCES

1	www.science.gov Internet Source	1%
2	repository.unhas.ac.id Internet Source	1%
3	R Tayeb, G Alam, E Pakki, Y Y Djabir. " Paliasa L.) Hepatoprotector "Tea Bag" preparation as supporting therapy in the use of fixed-dose combination of antituberculosis drugs ", Journal of Physics: Conference Series, 2019 Publication	1%
4	link.springer.com Internet Source	1%
5	Rouhollah Gazor, Fatemeh Niknezhad, Fatemeh Yousefbeyk, Monireh Aghajany-Nasab, Fahimeh Mohammadghasemi. "The Extract of Viola odorata Flowers Improves the Biochemical, Pancreas Histological, and Insulin Resistance Parameters in an Animal Model of Diabetes", Iranian Journal of Toxicology, 2022	1%

6	Abba Aji Manu, Bello Muhammad Musa, Martha Orendu Oche Attah, Helga Ishaya Bedan. "Ethanollic Extract of Syzygium cumini Causes Toxic Effects on Ethanol-induced Liver and Kidney Damage in Albino Wistar Rats: A Biochemical and Histological Study", Iranian Journal of Toxicology, 2022 Publication	1 %
7	innovareacademics.in Internet Source	1 %
8	www.researchgate.net Internet Source	1 %
9	www.hindawi.com Internet Source	1 %
10	irj.uswr.ac.ir Internet Source	1 %
11	media.neliti.com Internet Source	1 %
12	Ali Mandegary, Reza Kheirandish, Sepideh Heidari, Mansour Mirtadzadini, Amir Asadi, Navid Hassanabadi, Fariba Sharififar. "The Toxicity Evaluation of Salvia rhytidea and Glycine Max Extracts versus the Biochemical and Histological Indices of Liver and Kidney	<1 %

Functions in Mice", Iranian Journal of Toxicology, 2020

Publication

13

Submitted to American Collegiate Institute

Student Paper

<1 %

14

Mohammad Jamalain, Hassan Solhi, Parisa Ghasemi, Ali Rahbari, Amir Mohammad Kazemifar. "Prevention of Lung Complications following Paraquat Poisoning by Silymarin, N-acetyl Cysteine and Hydrocortisone: An Experimental Study", Iranian Journal of Toxicology, 2020

Publication

<1 %

15

www.msh.org

Internet Source

<1 %

16

www.sciencegate.app

Internet Source

<1 %

17

www.scholarsresearchlibrary.com

Internet Source

<1 %

18

www.tjnpr.org

Internet Source

<1 %

19

Submitted to Universitas Hasanuddin

Student Paper

<1 %

20

cyberleninka.org

Internet Source

<1 %

21 Tatyana Ushakova, Hovsep Melkonyan, Larisa Nikonova, Nicolai Mudrik et al. "The effect of dietary supplements on gene expression in mice tissues", Free Radical Biology and Medicine, 1996
Publication <1 %

22 Yulia Yusrini Djabir, Jumasni Adnan, Nurul Amalia, Nurfadillah Ramli, Sartini Sartini, Sukamto Salang Mamada, Usmar Usmar. "Roselle (Hibiscus sabdariffa L.) calyx water extract ameliorates isoniazid and rifampicin induced liver and renal injuries in rats", Journal of Herbmed Pharmacology, 2021
Publication <1 %

23 9lib.net
Internet Source <1 %

24 Hongxiu Ding, Yinyu Gao, Hanwu Lei, Liping Luo, Hongjuan Chao, Roger Ruan. "Antioxidant Effects of Flavonoids of Sweet Potato Vines ", International Journal of Food Properties, 2010
Publication <1 %

25 Submitted to Nottingham Trent University
Student Paper <1 %

26 Submitted to Universidad Estadual Paulista
Student Paper <1 %

27

Internet Source

<1 %

28

www.ijppsjournal.com

Internet Source

<1 %

29

Klenø, T. G., B. Kiehr, D. Baunsgaard, and U. G. Sidelmann. "Combination of 'omics' data to investigate the mechanism(s) of hydrazine-induced hepatotoxicity in Rats and to identify potential biomarkers", *Biomarkers*, 2004.

Publication

<1 %

30

pubmed.ncbi.nlm.nih.gov

Internet Source

<1 %

31

webbook.nist.gov

Internet Source

<1 %

32

Jin Xu, Xiaofang Long, Shijia Ge, Mengli Li, Lingzhu Chen, Deyu Hu, Yuping Zhang. "Deposition amount and dissipation kinetics of difenoconazole and propiconazole applied on banana with two commercial spray adjuvants", *RSC Advances*, 2019

Publication

<1 %

33

jurnal.unsyiah.ac.id

Internet Source

<1 %

34

rps.mui.ac.ir

Internet Source

<1 %

www.mdpi.com

35

Internet Source

<1 %

36

Haidy A. Gad, Sherweit H. El-Ahmady.
"Prediction of thymoquinone content in black
seed oil using multivariate analysis: An
efficient model for its quality assessment",
Industrial Crops and Products, 2018

Publication

<1 %

37

Submitted to Hong Kong Baptist University

Student Paper

<1 %

38

Surachai Techaoei, Chariya
Jirayuthcharoenkul, Khemjira Jarmkom,
Thisakorn Dumrongphuttidecha, Warachate
Khobjai. "Chemical evaluation and
antibacterial activity of novel bioactive
compounds from endophytic fungi in
Nelumbo nucifera", Saudi Journal of Biological
Sciences, 2020

Publication

<1 %

39

ijpjournal.com

Internet Source

<1 %

40

phj.rums.ac.ir

Internet Source

<1 %

41

publication.babcock.edu.ng

Internet Source

<1 %

42

www.spandidos-publications.com

Internet Source

<1 %

43

"20th International Congress of Nutrition: Granada, Spain, September 1520, 2013", Annals of Nutrition and Metabolism, 2013

Publication

<1 %

44

Carlos Montalvo Romero, Claudia Aguilar Ucán, Angel Sosa Peralta, Jesus Tagle Reyes et al. "Health Risk Assessment of Heavy Metals: Cu, Cd, Pb, Ni and Hg, in Catfish *Ariopsis felis* in Southern Mexico", Iranian Journal of Toxicology, 2022

Publication

<1 %

45

Monica Leopoldini, Nino Russo, Sandro Chiodo, Marirosa Toscano. "Iron Chelation by the Powerful Antioxidant Flavonoid Quercetin", Journal of Agricultural and Food Chemistry, 2006

Publication

<1 %

46

brief.land

Internet Source

<1 %

47

dergi.fabad.org.tr

Internet Source

<1 %

48

locus.ufv.br

Internet Source

<1 %

49

www.agrojournal.org

Internet Source

<1 %

50 www.iau.edu.sa <1 %
Internet Source

51 "Black cumin (*Nigella sativa*) seeds: Chemistry, Technology, Functionality, and Applications", Springer Science and Business Media LLC, 2021 <1 %
Publication

52 Dogukan Canayakin, Yasin Bayir, Nurcan Kilic Baygutalp, Esen Sezen Karaoglan et al. "Paracetamol-induced nephrotoxicity and oxidative stress in rats: the protective role of ", *Pharmaceutical Biology*, 2016 <1 %
Publication

53 *Edible Medicinal And Non-Medicinal Plants*, 2013. <1 %
Publication

Exclude quotes On

Exclude matches < 5 words

Exclude bibliography On